

Skin Biopsies and Excisions

Specimen Handling and Margin Assessment

The way that specimens are handled in the laboratory will depend on the type of sample, their size and shape, and whether they have been taken for inflammatory or neoplastic conditions. Marking sutures or nicks will also alter handling.

EXCISION SPECIMENS

(e.g. elliptical, shave/saucerisation, punch)

These are inked on all surgical margins to enable histological recognition as such.

When specimen orientation has been specified, the specimen may be scored along a border or different ink colours may be used. A diagram is usually drawn and this can be helpful to clinicians when margins are involved.

The way the specimen is cut will depend on its size and shape.

- ▶ Most punch excisions and shave excisions are bi- or trisected, depending on their diameter. Even if such specimens have been orientated, margins can only be examined and measured in the plane of sectioning (see figure 1). As shave specimens are generally cut along the longest plane to limit fragmentation, the margins assessed also tend to be the ones that are furthest from the lesion.
- ▶ Elliptical excisions that are approximately 10mm in maximum dimension can be cut in 3-4mm thick parallel 'bread loaf' slices and submitted completely (see figure 2). For longer excisions, the entire lesion is submitted in parallel slices and longitudinal sections to the points of the ellipse are also submitted. This allows examination and accurate measurement of all margins (see figure 2). For ill-defined lesions, the entire specimen is generally submitted in parallel slices.
- ▶ Other shapes are cut in a similar manner, with modifications (see figure 3).
- ▶ Tiny ellipses (3-4mm) are generally treated as a small punch specimen and margins can only be accurately examined and measured in the plane of sectioning.
- ▶ Samples of pigmented lesions from acral sites are cut perpendicular to the dermatoglyphs (skin ridges/furrows) as parallel sections can result in a false positive result of melanoma as a result of profiling long, confluent junctional nests.

Figure 1 - Punch Excision

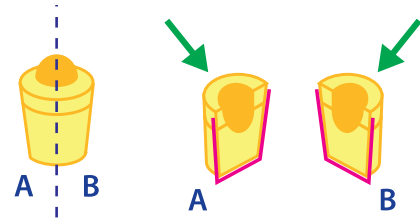
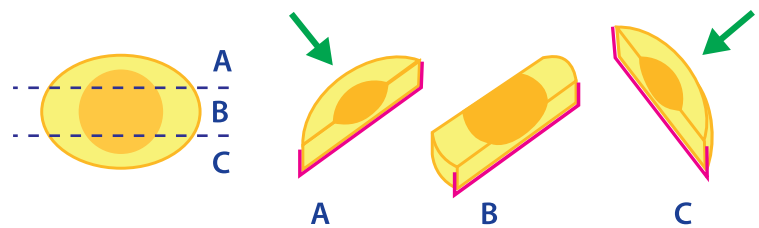


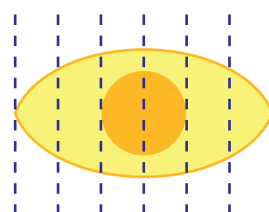
Figure 1 - Shave Excision



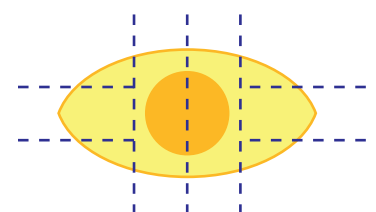
— Margins assessable in histological section

→ Margins not assessable in the plane of sectioning

Figure 2

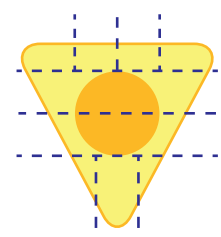
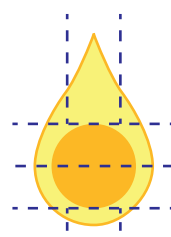


Parallel 'bread loaf' slices



Parallel slices of lesion with longitudinal slices to points of ellipse

Figure 3



>>> Continued Overleaf

PARTIAL BIOPSIES (punch, shave, incisional)

- ▶ Small punch biopsies (up to 4mm) are submitted whole.
- ▶ Superficial shave biopsies are cut in parallel slices, usually in the longitudinal plane, to limit fragmentation.
- ▶ Incisional biopsies are mostly performed for inflammatory conditions and are either submitted in total without being cut, if no wider than 4mm, or they are bisected in the longitudinal plane to allow optimal visualisation of the inflammatory process.
- ▶ Requests for margins are sometimes received for such specimens and it should be noted that they are only reliable in the plane of sectioning.

MARGIN MEASUREMENTS

Histological margin measurements are provided to reflect the likelihood that a malignant tumour will recur. Although there is no absolute guarantee that recurrence will not occur, in general, this risk reduces with increasing distance of the margin. The Cancer Council Australia/Australian Cancer Network provides minimum histological margin recommendations for squamous and basal cell carcinoma. It should be noted, however, that there are limitations to the accuracy and reproducibility of histological measurements.

- ▶ **Tissue retraction:** This is more prominent in more elastic or muscular tissues, and less pronounced when solar damage is prominent. Tumour also retracts less than normal tissues.
- ▶ **Tissue sampling:** Accuracy increases with the number of tissue slices and histological sections examined. Each histological section is approximately 3-4µm thick, thus representing only 0.001% of each 3-4mm tissue slice. Even when multiple sections or levels have been examined, only a small percentage of the actual tumour has been examined.
- ▶ **Ill-defined margins:**
 - In some melanomas, single atypical melanocytes extend beyond the clinically visible lesion, making accurate or reproducible measurement virtually impossible.
 - There is often a continuum of changes in the spectrum of solar keratosis to in situ squamous cell carcinoma, which is often non-linear. Determining where such lesions start and end is poorly reproducible amongst pathologists.

Even when tumour is present at a margin, residual tumour may not be identified at re-excision. Positive margins also do not predict tumour recurrence. A variety of factors play a role, including tumour type, histological subtype and involved margin(s). Involvement of the deep margin confers almost double the risk of recurrence when compared to peripheral margin involvement.

EN FACE MARGIN ASSESSMENT

This is generally not performed on small, formalin-fixed specimens as both false positive and negative results can result from tissue retraction ex vivo. This method is most effective when used in Mohs micrographic surgery where the margins are assessed en face by frozen section. This allows a larger surface area to be assessed when compared to conventional parallel slices, resulting in lower local recurrence rates when narrow excision margins cannot be avoided.

For further information please contact:

Dr Patricia Renaut FRCPA; MBBS; BSc (Hons)
Consultant Histopathologist
Dermatopathologist

P: (07) 3121 4607 **E:** Patricia.Renaut@qml.com.au

Dr Debra Norris FRCPA; MBBS (HONS)
Pathologist in Charge - Histology

Haematopathologist (member EAHP), Dermatopathologist

P: (07) 3121 4444 **E:** DNorris@qml.com.au