

Primary Cutaneous CD30+ Lymphoproliferative Disorders

This group consists of **lymphomatoid papulosis (LyP)** and **primary cutaneous anaplastic large cell lymphoma (cALCL)**. After mycosis fungoides (MF), this is the second most common group of primary cutaneous T-cell lymphoma (CTCL), accounting for 25-30% of all CTCL. LyP and cALCL represent two ends of a spectrum of disease and have an excellent prognosis. They share histopathological and molecular similarities, being distinguishable only by clinicopathological correlation. Some cases defy accurate classification and are 'borderline' between the two.

CD30 expression can also be seen in any stage of MF, particularly in transformed cases and it is important to distinguish this from LyP and cALCL as the prognosis and treatment are quite different. Whilst a diagnosis of cALCL should never be made in a patient with a history of MF or other CTCL, 10-20% of patients with LyP have, have had or will develop, another type of lymphoma such as MF, cALCL or Hodgkin lymphoma. CD30 expression can also be seen in immunosuppression-related lymphoproliferative disease and a history of immunosuppression excludes a diagnosis of LyP or cALCL. cALCL also requires distinction from cutaneous involvement by systemic anaplastic large cell lymphoma, which has a worse prognosis.

LYMPHOMATOID PAPULOSIS

Clinical

- ▶ Generally seen in young adults, but can also be seen in children and the elderly
- ▶ Presents as a generalised eruption or a small crop of papular/papulonecrotic/nodular lesions in different stages of evolution on the trunk and limbs
- ▶ The lesions are usually <1cm, but large nodules may also occur
- ▶ The lesions are self-limiting, disappear in 3-12 weeks +/- scarring but recur after a variable period
- ▶ The duration of disease may be months to years (>40 years has been described)
- ▶ 10-20% of patients have, have had or will develop, another type of lymphoma such as MF, cALCL or Hodgkin lymphoma
- ▶ Patients with classic LyP, based on clinicopathological correlation, do not require complete staging investigations in the absence of specific symptoms of other associated diseases

Histopathology

- ▶ Variable, in part correlating with the age of the lesion that has been biopsied
- ▶ Currently the WHO classification recognises at least 6 variants (types A, B, C, D, E and LyP with 6p25 rearrangement), along with other newly proposed variants e.g. type F (folliculotropic) and those with γ/δ phenotype
- ▶ The different subtypes do not confer any prognostic information but are important to recognise as they show morphologic/immunophenotypic overlap not only with cALCL but also with other more aggressive CTCLs that have a poor prognosis

Immunophenotype

- ▶ Depending on the subtype, there may be scattered or clustered large cells that are CD30+ and ALK-
- ▶ The large cells are CD3+ T cells that may be CD4+ or CD8+
- ▶ Pan-T-cell antigens may be lost

Genetics

- ▶ T-cell receptor (TCR) gene rearrangement is found in most cases; most are α/β but γ/δ is occasionally seen
- ▶ t(2;5) is absent

>>> Continued Overleaf

Prognosis

- ▶ Excellent; 100% 5-year survival
- ▶ Variable length of remission between recurrences
- ▶ 10-20% patients have or will develop an associated lymphoma, therefore, long term follow-up is required

Treatment

- ▶ None of the available treatment options affect the natural course of the disease, which is self-limiting but chronic and relapsing, or the development of another lymphoma
- ▶ Recurrence is the rule, following cessation of treatment
- ▶ Patients with relatively few or non-scarring lesions do not require active treatment
- ▶ Treatment may be skin-directed or systemic but the short term benefits must be balanced against the potential toxic/carcinogenic side-effects
- ▶ The most commonly used skin directed therapies include topical steroids and phototherapy. With the latter, there is an increased risk of both melanoma and non-melanoma skin cancers
- ▶ The most commonly used systemic therapy is low-dose methotrexate. This approach should only be considered in patients with extensive disease

PRIMARY CUTANEOUS ANAPLASTIC LYMPHOMA

Clinical

- ▶ Affects mainly adults
- ▶ Most cases present with solitary nodules/tumours that often ulcerate but multiple lesions or multifocal involvement can also occur
- ▶ Spontaneous complete or partial regression of lesions has been reported in up to 44% of patients
- ▶ No prior history of LyP, MF or other CTCL
- ▶ Complete staging investigations are required to exclude secondary involvement by systemic ALCL
- ▶ The finding of regional nodal involvement at staging investigations does not alter the prognosis when compared to skin-localised disease (concomitant cutaneous and nodal anaplastic large cell lymphoma)

Histopathology and immunophenotype

- ▶ Nodular or diffuse sheets of large CD30+ lymphocytes in dermis +/- subcutis
- ▶ These are CD3+ T cells that may be CD4+ or CD8+
- ▶ Pan-T-cell antigens may be lost
- ▶ ALK is usually negative but ALK+ cases have been reported in children

Genetics

- ▶ TCR gene rearrangement
- ▶ t(2;5) is absent

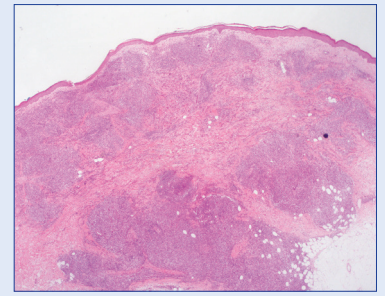


Fig 1: H&E

Wedge-shaped infiltrate extending into subcutis.

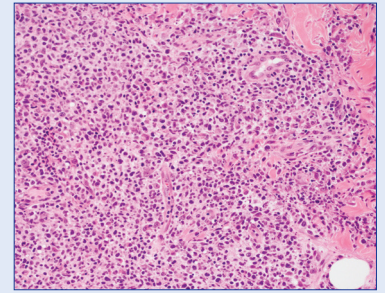


Fig. 2 Higher magnification showing sheets of atypical, large lymphoid cells with irregular nuclei.

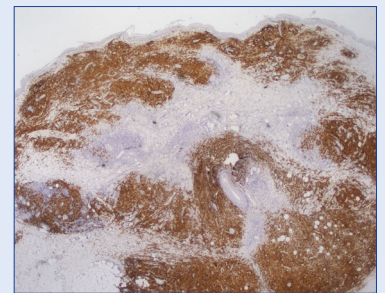


Fig. 3 CD30 Positive in >75% of cells.

Prognosis

- ▶ >90% 5-year survival (compared to 50% in systemic ALK- ALCL)

Treatment

- ▶ Solitary lesions: Excision and/or radiotherapy
- ▶ Multifocal lesions: Radiotherapy, methotrexate, oral retinoids, interferon- α

DIAGNOSTIC WORKUP AND STAGING FOLLOWING BIOPSY SUGGESTING CD30+ LPD

Following a histology report suggesting a primary cutaneous CD30+ lymphoproliferative disorder, a detailed clinical history should be taken. This should be followed by thorough examination +/- investigations, as dictated by the clinical history and examination findings.

History

- ▶ Previous lymphoma: MF, other CTCL, Hodgkin lymphoma, systemic anaplastic large cell lymphoma
- ▶ A history of atypical 'eczema' or 'dermatitis' may also be pertinent and reflect misdiagnosed MF
- ▶ Natural history of lesions (waxing/waning, recurring)
- ▶ Immunosuppression
- ▶ B-symptoms: Fever, night sweats, weight loss

Physical examination

- ▶ Number and size of lesions
- ▶ Presence of MF-type lesions (patches or plaques)
- ▶ Lymphadenopathy (>1.5cm in greatest dimension)
- ▶ Hepatosplenomegaly

Blood tests

- ▶ FBC and differential
- ▶ Biochemistry including LDH

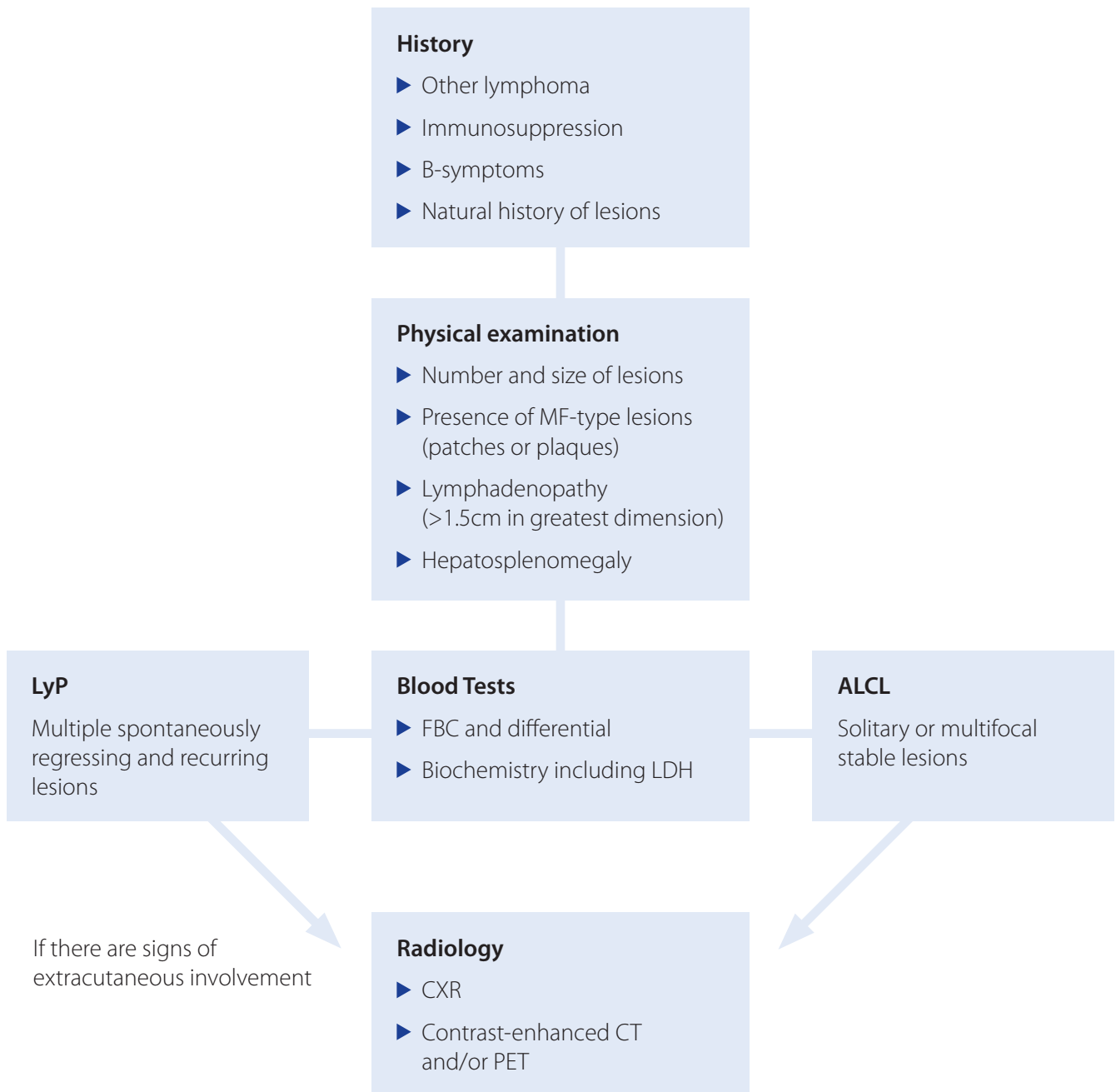
Radiology

- ▶ Not required if clinical picture is of typical LyP and there are no signs of extra-cutaneous involvement
- ▶ If there are signs of extracutaneous involvement or the picture is of cALCL, investigate with CXR, contrast-enhanced CT and/or PET

Lymph node biopsy

- ▶ If there is lymphadenopathy (>1.5cm in greatest dimension)

Biopsy suggesting CD30+ lymphoproliferative disorder



For further information please contact:

Dr Patricia Renaut FRCPA; MBBS; BSc (Hons)
Consultant Histopathologist
Dermatopathologist

P: (07) 3121 4607 **E:** Patricia.Renaut@qml.com.au

Dr Debra Norris FRCPA; MBBS (HONS)
Pathologist in Charge - Histology
Haematopathologist (member EAHP), Dermatopathologist

P: (07) 3121 4444 **E:** DNorris@qml.com.au