

Merkel Cell Carcinoma

An Update on the Disease and its Management

Key points

- ▶ MCC is a relatively rare but potentially aggressive tumour.
- ▶ Overall mortality is twice that for melanoma.
- ▶ Progression can be rapid and urgent referral is essential.
- ▶ Sentinel node biopsy may be required for staging.
- ▶ Radiation therapy is an integral part of the treatment.
- ▶ Large excisions or flap repair may alter the tumour bed and compromise sentinel node biopsy or radiation therapy.
- ▶ Avelumab is a PD-L1 inhibitor that has received FDA approval for metastatic MCC.

MERKEL CELL CARCINOMA

Merkel cell carcinoma (MCC) is a cutaneous neuroendocrine carcinoma that is relatively rare, but potentially aggressive. Whilst it is mainly seen in older people and is related to UV exposure, it also occurs in younger individuals who are immunosuppressed from a variety of causes such as organ transplantation, HIV infection and chronic lymphocytic lymphoma. As for other tumours that are related to UV exposure, the incidence rates of MCC in Australia and New Zealand are higher than in other parts of the world. Based on data from 1993-2010, the incidence rate in Queensland is the highest in Australia (1.6 per 100,000 population) and at least double that of anywhere else in the world.

MERKEL CELL POLYOMAVIRUS AND GENETICS

In 2008, the Merkel cell polyomavirus (MCPyV) was discovered. This belongs to the expanding group of human polyomaviruses that also includes JC- and BK-polyomaviruses, and has been detected in up to 80% of cases of MCC. In MCPyV-positive cases, viral DNA is found to be clonally integrated into the tumour. In Australia, the association between MCC and MCPyV is only approximately 24% as the majority of cases are related to UV-damage.

Genomic studies have demonstrated distinct patterns of genomic alterations in virus-positive and -negative tumours, with the latter showing greater genomic instability and a higher rate of mutations. Regardless of the mechanism, both pathways result in the disruption of the retinoblastoma (Rb) protein, which is a tumour suppressor. The distinct mutation profiles are being exploited as potential therapeutic targets.

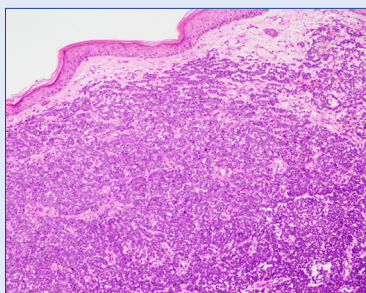
CLINICAL

There are no particular distinguishing clinical features for Merkel cell carcinoma. It is usually a painless, firm, red to violaceous nodule that grows rapidly in sun-exposed sites (usually head, neck and upper extremities) although other sites can be affected in immunosuppressed individuals. The 'AEIOU' acronym has been used as an aid in the recognition of MCC.

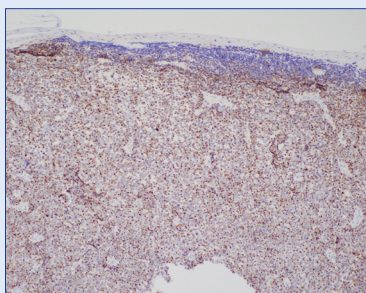
- ▶ Asymptomatic
- ▶ Expanding rapidly
- ▶ Immunosuppressed
- ▶ Older than 50
- ▶ UV-exposed site

Whilst most patients present with clinically localised disease, 35% present with nodal disease and up to 14% present with distant metastasis. Metastasis to regional and distant sites can be rapid and the overall mortality rate is twice that of cutaneous melanoma (33% vs 15%). Even the smallest primary tumour is associated with at least a 10-20% risk of occult nodal metastasis at the time of diagnosis. In 8-12% of cases, MCC presents as a nodal metastasis without a known or detectable primary cutaneous tumour and these cases have a more favourable prognosis compared to those presenting with a primary tumour and synchronous metastasis.

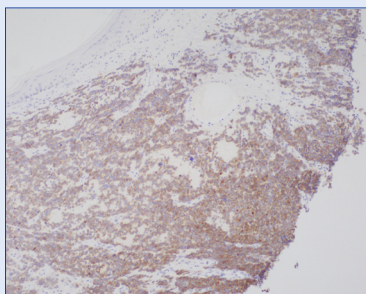
>>> Continued Overleaf



H & E



CK20



Synaptophysin

This may be a reflection of the success of the host immune response in destroying the primary tumour. Spontaneous regression of MCC, including metastases, is a well documented phenomenon that has been ascribed to host immune response activation. This is also seen in cases of immunosuppression-associated MCC where the cessation of immunosuppression can result in tumour regression.

As for other neuroendocrine carcinomas, paraneoplastic syndromes such as cerebellar degeneration, Lambert-Eaton myasthenic syndrome and hyponatraemia can occur in patients with MCC and, in some cases; this may be the presenting symptom.

DIAGNOSIS AND PATHOLOGY

The diagnosis is made by biopsy, either partial or excisional. Immunohistochemistry is required for diagnosis and the main differential diagnosis based on morphology includes metastatic small cell carcinoma and lymphoma. Misdiagnosis as basal cell carcinoma is well documented and some tumours can show squamous differentiation as well as features that are suggestive of melanocytic differentiation. Terminal deoxynucleotidyl transferase (TdT) has also been found to be expressed in a significant number of MCC, which may lead to misdiagnosis as lymphoblastic lymphoma if only a limited panel of immunohistochemistry is employed.

Currently, there is no recommended histological grading system and histological subtype (intermediate, small cell or trabecular) has not been shown to be reproducible or of prognostic significance. The growth pattern of the tumour should be recorded (circumscribed/nodular or infiltrative). Breslow thickness and tumour-infiltrating lymphocytes should be reported as for melanoma (a brisk response is associated with a better prognosis). p63 expression has been shown to be associated with a more aggressive course and is an important predictor of shorter survival in MCC cases from Europe and North America; however, this association has not been found in cases from an Australian study and this is not routinely performed. Other parameters that need to be recorded in the pathology report include tumour lymphovascular invasion, size of largest nodal metastasis, presence of extranodal extension and presence of isolated tumour cells in regional nodes.

MANAGEMENT

Following a histological diagnosis of Merkel cell carcinoma, the patient should undergo full clinical examination of skin and regional lymph nodes. Baseline blood tests including full blood count, biochemistry and coagulation, along with staging scans should be performed. Although there is increasing evidence that PET-CT offers increased sensitivity over conventional CT and MRI, the use of this modality for Merkel cell carcinoma does not currently attract Medicare funding. MRI is more sensitive than CT for the detection of brain metastases. Tissue biopsy confirmation of metastasis is recommended as false positive radiology results may occur.

SENTINEL LYMPH NODE BIOPSY (SLNB)

For patients with disease that is localised to the skin and without clinical/radiological evidence of metastasis, SLNB is important to complete the staging process. SLNB should also be considered in patients who have clinically palpable but radiologically negative lymph nodes.

It is usually performed at the time of definitive wide local excision. It should be noted that the success rate of identifying the draining sentinel lymph node may be impaired if the patient has already had a wide excision or flap repair as this may disrupt the lymphatic drainage. There are also site-related difficulties in the detection of sentinel lymph nodes in the head and neck. In this location, the draining nodes are often close to the primary tumour and they may be obscured by the injected tracer. The risk of surgical complications is also higher due to the proximity of nerves and blood vessels.

When it is not appropriate to perform SLNB due to high surgical risk, ultrasound evaluation with fine needle aspiration biopsy may be a suitable alternative. In patients who are not surgical candidates, SLNB is usually not performed and the nodal basin should be irradiated.

EXCISION AND MARGIN CLEARANCE

The primary tumour should be treated by excision; however, there is no evidence-based consensus recommendation for either surgical or histological margins. Although older studies recommend wide surgical margins of 2-3cm, more recently, the trend is for a narrower surgical margin of 1-2cm, regardless of tumour size, followed by adjuvant irradiation of the tumour bed. Tumours with positive histological margins should be re-excised, but there is no minimum histological margin required. Mohs surgery is also used and, in this setting, it is recommended that the central portion of the tumour be sent for permanent section analysis.

RADIATION THERAPY (RT)

Most trials have shown that adjuvant RT reduces the risk of recurrence compared to surgery alone; however, there is a lack of consensus regarding its use in MCC. Whilst some experts do not consider RT to be necessary in stage 1 tumours with histological clear margins, the National Comprehensive Cancer Network (NCCN) recommends post-operative RT regardless of stage.

RT alone of the primary tumour and/or regional nodal basin can be used as the definitive treatment for patients who are unable to tolerate surgery or as palliation in inoperable cases.

LYMPHADENECTOMY

Patients with clinical nodal disease should undergo completion lymphadenectomy (CL). Adjuvant RT of the nodal basin is also recommended if there is extensive disease with extranodal spread. Whilst the current recommendation for positive SLNB is CL and/or RT, it is unclear whether CL provides additional benefit compared to RT alone.

CHEMOTHERAPY (CT)

Adjuvant CT is not recommended as it does not provide a clear benefit. CT is reserved for the treatment of metastatic disease, which usually occurs within the first 3 years of diagnosis, affecting lymph nodes first, followed by distant skin, lung, CNS, bone and liver. Whilst MCC is chemosensitive, CT only provides short term benefit and most cases recur within 4 to 15 months..

IMMUNOTHERAPY

In March 2017, the drug Avelumab, which is a programmed death ligand-1 (PD-L1) inhibitor, received accelerated FDA approval in the USA for the treatment of metastatic MCC in adults and paediatric patients aged ≥ 12 years. PD-L1 is thought to play a major role in immune suppression and high levels are found in virus-negative MCC. Avelumab, therefore, acts by activation of the immune response. Several clinical trials including other immune modulators are ongoing.

FOLLOW UP

Most recurrences present within 3 years of diagnosis of the primary cutaneous tumour. The suggested follow up interval is every 3-6 months for the first 2 years, reducing to every 6-12 months.

References

1. Youlden DR et al. Incidence and survival for Merkel cell carcinoma in Queensland, Australia, 1993-2010. *JAMA Dermatol.* 2014;150(8):864.
2. Feng H et al. Clonal Integration of a Polyomavirus in Human Merkel Cell Carcinoma. *Science.* 2008;319(5866):1096. Epub 2008 Jan 17.
3. Garneski KM et al. Merkel Cell Polyomavirus is More Frequently Present in North American than Australian Merkel Cell Carcinoma Tumors. *Journal of Investigative Dermatology* (2009) 129, 246–248; doi:10.1038/jid.2008.229; published online 24 July 2008.
4. Dabner M et al. Merkel cell Polyomavirus and p63 status in Merkel cell carcinoma by immunohistochemistry: Merkel cell Polyomavirus positivity is inversely correlated with sun damage, but neither is correlated with outcome. *Pathology* (2014) 46(3), 205-210.
5. Goh G et al: Mutational landscape of MCPyV-positive and MCPyV-negative Merkel cell carcinomas with implications for immunotherapy. *Oncotarget* 7:3403-3415, 2016.
6. Wong SQ et al: UV-associated mutations underlie the etiology of MCV-negative Merkel cell carcinomas. *Cancer Res* 75:5228-5234, 2015.
7. Harms PW et al: Next generation sequencing of cytokeratin 20-negative Merkel cell carcinoma reveals ultraviolet-signature mutations and recurrent TP53 and RB1 inactivation. *Mod Pathol* 29:240-248, 2016.
8. Veija T, Sarhadi VK, Koljonen V, et al: Hotspot mutations in polyomavirus positive and negative Merkel cell carcinomas. *Cancer Genet* 209:30-35, 2016.
9. Harms PW, Vats P, Verhaegen ME, et al: The distinctive mutational spectra of polyomavirus-negative Merkel cell carcinoma. *Cancer Res* 75:3720-3727, 2015 .
10. Cimino PJ et al: Retinoblastoma gene mutations detected by whole exome sequencing of Merkel cell carcinoma. *Mod Pathol* 27:1073-1087, 2014.
11. Heath M et al: Clinical characteristics of Merkel cell carcinoma at diagnosis in 195 patients: The AEIOU features. *J Am Acad Dermatol* 58:375-381, 2008.
12. Lemos BD et al: Pathologic nodal evaluation improves prognostic accuracy in Merkel cell carcinoma: Analysis of 5823 cases as the basis of the first consensus staging system. *J Am Acad Dermatol* 63:751-761, 2010.
13. Iyer JG et al. Relationships among primary tumor size, number of involved nodes, and survival for 8044 cases of Merkel cell carcinoma. *J Am Acad Derm.* 70:647-643, 2014.
14. Schwartz JL et al. Features predicting sentinel lymph node positivity in Merkel cell carcinoma. *J Clin Oncol* 29:1036-1041, 2011.
15. Tarantola TI et al. Unknown primary Merkel cell carcinoma: 23 new cases and a review. *J Am Acad Dermatol* 68:433-440, 2013.
16. Chen KT, et al. A better prognosis for Merkel cell carcinoma of unknown primary origin. *Am J Surg* 206:752-757, 2013.
17. Foote M et al. Merkel cell carcinoma: the prognostic implications of an occult primary in stage IIIB (nodal) disease. *J Am Acad Derm* 67:395-399, 2012.
18. Ma JE , Brewer JD: Merkel cell carcinoma in immunosuppressed patients. *Cancers (Basel)* 6:1328-1350, 2014.
19. Iyer JG et al. Paraneoplastic syndromes (PNS) associated with Merkel cell carcinoma (MCC): A case series of 8 patients highlighting different clinical manifestations. *J Am Acad Dermatol* 75:541-547, 2016.
20. Ball NJ and Tanhuanco-Kho G. Merkel cell carcinoma frequently shows histologic features of basal cell carcinoma: a study of 30 cases. *J Cutan Pathol* 34:612-619, 2007.
21. Buresh CJ et al. Reactivity with TdT in Merkel cell carcinoma: a potential diagnostic pitfall. *Am J Clin Pathol* 129:894-898, 2008.
22. Righi A et al. An ultrasonography-cytology protocol for the diagnostic management of regional nodes in a subset of patients with Merkel cell carcinoma of the skin. *Br J Dermatol.* 168:563-570, 2013.
23. Desch L and Kunstfeld R. Merkel cell carcinoma: Chemotherapy and emerging new therapeutic options. *J Skin Cancer.* 2013;2013:327150.
24. National Comprehensive Cancer Network. NCCN Clinical Practice Guidelines in Oncology: Merkel Cell Carcinoma. 2016

For further information please contact:

Dr Patricia Renaut FRCPA; MBBS; BSc (Hons)
Consultant Histopathologist
Dermatopathologist

P: (07) 3121 4607 **E:** Patricia.Renaut@qml.com.au

Dr Debra Norris FRCPA; MBBS (HONS)
Pathologist in Charge - Histology

Haematopathologist (member EAHP), Dermatopathologist

P: (07) 3121 4444 **E:** DNorris@qml.com.au