

Atypical Pigmented Lesions

A Pragmatic Approach to Atypical Pigmented Lesions That Pose Problems for Clinicians and Pathologists.

Dr Patricia Renaut

Key points

- ▶ There is no evidence that patients with one or a few of these naevi have a higher risk of developing melanoma.
- ▶ There is no evidence that dysplastic naevi are any more likely than common naevi to be direct precursors of melanoma.
- ▶ The correlation between clinically atypical naevi and histologically diagnosed dysplastic naevi is poor to fair.
- ▶ Only naevi that are clinically suspicious for melanoma need to undergo excision biopsy.
- ▶ A two-tier histological grading system for atypia reduces interobserver variability and makes management pathways clearer.
- ▶ Lesions that are low grade or without atypia do not need to be re-excised if there is no clinically visible residual lesion.
- ▶ High grade/atypical lesions with positive histological margins should be re-excised with a narrow margin of normal skin.
- ▶ Lesions that are favoured to be melanoma in situ should be stated as such in the pathology report.

Note: This discussion does not apply to 'lentiginous dysplastic naevus of the elderly' or similarly named lesions that appear to be *bona fide* premalignant lesions lying somewhere along the spectrum of atypical lentiginous melanocytic proliferation and lentiginous melanoma. This is discussed in a separate section.

DYSPLASTIC NAEVI

The dysplastic naevus continues to be a subject of controversy and cause of dissent amongst pathologists and skin cancer doctors, alike. This arises from the term 'dysplastic' and also the three-tier histological grading system of atypia (mild, moderate and severe), both of which suggest that there is a linear relationship and stepwise progression from dysplastic naevus to melanoma. The resulting overtreatment of many dysplastic naevi has led to several attempts to abandon the name and grading system.

From observations of clinically atypical naevi in patients with a familial predisposition to melanoma, the suggestion that dysplastic naevi are a marker for an increased melanoma risk was made. These early observations were, however, based on the presence of clinically atypical naevi rather than histologically diagnosed dysplastic naevi (DN) and it is now known that there is only poor to fair correlation between the two. Although it is widely stated that DN are a marker for increased melanoma risk, this is only true in patients with high numbers of naevi. It also holds true for patients with high numbers of common naevi.

To date, there is no evidence that DN are any more likely than common naevi to be precursors of melanomas. Both are found in association with melanomas in roughly equal proportions. There are also no consistently reproducible genetic alterations that link DN to melanomas. Thus, the three-tier histological grading system of atypia becomes questionable. This is even more so when considering the subjective nature of grading: one pathologist's dysplastic naevus with severe atypia may be another's melanoma in situ, and lesions with mild atypia may be a common naevus to another pathologist. This interobserver variability should be taken into consideration when interpreting the results of any study that purports to correlate the severity of atypia with increased melanoma risk.

Grading is also problematic as based on the current grading system all DN will show at least mild atypia. This is only so when they are compared to common naevi. Some of the histological features that are used to diagnose and grade DN are also seen and recognised to be normal features in so called 'special site' naevi, scalp naevi in children, Spitz naevi and pigmented spindle cell naevi, all of which are unequivocally benign naevi that look atypical only when compared to the common naevus. When considered in this light, there is logic to the suggestion that the term 'dysplastic nevus' be replaced with 'Clark nevus' as it is a specific histological entity which is not truly dysplastic but deserves continued distinction from common naevi. Nevertheless, until there is universal agreement to change the name, the term 'dysplastic naevus' must still appear in the pathology report, even if only within parentheses, to avoid further confusion.

>>> Continued Overleaf

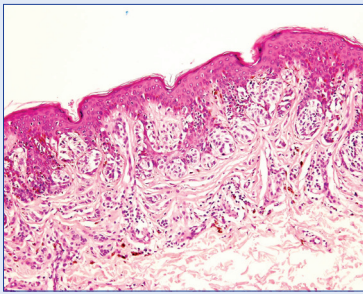


Fig. 1: Dysplastic naevus

Random cytological atypia, variation in size, shape and placement of nests of naevus cells, fibrosis and inflammation of stroma.

There is also considerable support for replacing the current grading system with a two-tier system (eg 'dysplastic naevus with low/high grade atypia' or 'Clark (dysplastic) nevus without/with atypia'). Whilst this does not eliminate subjectivity, it should be reduced considerably. It should be noted that the true utility of grading in this context is not to confer a risk of developing melanoma but, rather, to convey that there is diagnostic uncertainty. Lesions that are high grade or have atypia lie in the 'gray zone' between naevus and melanoma in situ. Whilst diagnostic uncertainty is inevitable in some cases, lesions that are favoured to be melanoma in situ should be stated as such, rather than using vague terms such as 'bordering on' or 'approaching'. This is to avoid confusion and to convey the necessity for appropriate margins. In pathology, diagnostic uncertainty is largely due to the subjectivity of histological assessment criteria and it is seen in many types of tumours. Advances in molecular analysis have allowed some of these 'gray zone' tumours to be reclassified and it is almost certain that further advances will result in the diminution of diagnostic uncertainty. Examples of this are the HRAS-mutated Spitz naevus and BAPomas, two genetically distinct tumours that were previously included in the 'atypical Spitz tumour' category. Both are now considered to be benign.

For reasons already mentioned above, not all clinically atypical naevi need to be removed. Patients should be assessed according to the prevailing pattern ('signature') of their naevi and only the 'ugly ducklings' that are suspicious for melanoma require removal. As for any lesion that is suspicious for melanoma, excisional biopsy is the gold standard. In patients with multiple naevi, this can be effectively performed by saucerisation to include a narrow (0.5-1mm) rim of normal skin beyond the pale brown halo. This minimises skin loss when compared to elliptical excisions. Note that well-performed saucerisation should include reticular dermis. The sample can also be placed onto a piece of card prior to immersion in formalin, to prevent excessive curling for optimal margin assessment. If there is residual pigment in the resulting wound, this must also be completely removed and sent for histology.

Naevi that are low grade or without atypia are benign and do not need to be re-excised, provided that there is no residual clinical lesion. This is to ensure that the lesion has not been undersampled by partial biopsy. High grade/atypical lesions should be completely excised with a margin of normal skin. Repeat saucerisation and excision with suture closure are both acceptable methods for re-excising these lesions.

Key points

- ▶ Lentigo maligna (LM) is a type of melanoma in situ and should be distinguished from atypical lentiginous melanocytic proliferations. The latter is an early precursor lesion that often co-exists with LM.
- ▶ LM lesions are made up of a mixture of melanocytic and non-melanocytic lesions. Partial biopsy is therefore, likely to lead to underdiagnosis.

LENTIGO MALIGNA

Lentigo maligna (LM) is listed in the 2006 WHO classification of skin tumours as a subtype of melanoma in situ occurring in severely sun-damaged skin. This definition is in contrast to that used by some authorities, who restrict the use of the term to a precursor of melanoma that comprises a proliferation of single atypical melanocytes without confluent growth, nesting or Pagetoid spread. This difference in opinion has caused considerable confusion.

For uniformity and clarity, the WHO definition should be adopted. The term 'lentigo maligna' should not be used to describe an 'atypical lentiginous melanocytic proliferation', which should be described as such. For further disambiguation, the phrase 'melanoma in situ, lentigo maligna type', can also be used.

LM typically occurs on the face and is large, with mottled areas of different colours. These polymorphous areas represent a mixture and collision of melanocytic and pigmented non-melanocytic lesions, with regression playing a part in the appearance. The melanocytic areas are often variable in appearance,

- ▶ If complete excision is not feasible, multiple shave biopsies should be taken to sample each different area/colour.
- ▶ Histological margins can be difficult to define.
- ▶ There are promising results for the use of topical Imiquimod as adjuvant therapy when histological clearance has not been achieved.

comprising an atypical lentiginous melanocytic proliferation that transitions into areas of melanoma in situ or even invasive melanoma. The superimposed non-melanocytic lesions often include solar lentigo, seborrhoeic keratosis, pigmented solar keratosis and intraepidermal carcinoma. For these reasons, partial biopsy is prone to underdiagnosis and multiple shave biopsies to sample each different area/colour should be performed, if complete excision is not feasible. As width rather than depth is desirable, shave biopsies are preferred to punches and these are also more acceptable to the patient for healing and cosmesis.

Histological margins for LM can be very difficult to define, for the reasons stated above; however, provided that histological margins are clear of the melanoma in situ component and a clinical excision margin of 5mm has been achieved, it is unnecessary (and often impossible) to achieve histological clearance from the single atypical melanocytes that often extend well beyond the limits of the visible lesion. Although they are precursor lesions, they take a long time to progress. Recent studies have reported promising long term results using topical Imiquimod for adjuvant treatment when histological clearance has not been achieved. Confocal microscopy has also been used to monitor these patients.

Key point

- ▶ This is a precursor of melanoma that shares similarities with lentigo maligna, and should be treated as such.

LENTIGINOUS DYSPLASTIC NAEVUS OF THE ELDERLY/LENTIGINOUS MELANOMA

This is a controversial entity that has been described by different names. First described by Kossard in 1991, subsequent authors have described this lesion as lentiginous melanoma. It shares many clinical characteristics with LM but shows some histological differences. As with LM, the evolution from atypical lentiginous melanocytic proliferation to melanoma in situ is slow, taking in excess of 10 years in many reported cases. The name 'lentiginous dysplastic naevus of the elderly' should be avoided as this is a recognised precursor to malignant melanoma that has no biological relationship with true dysplastic/Clark naevus.

As with LM, lesions are often large and ill-defined, therefore partial biopsy is prone to underdiagnosis. As most lesions are on the back/trunk/limbs, they are amenable to complete excision and saucerisation is also acceptable in this case. The same problem with drifting single atypical melanocytes, as in LM, may be encountered.

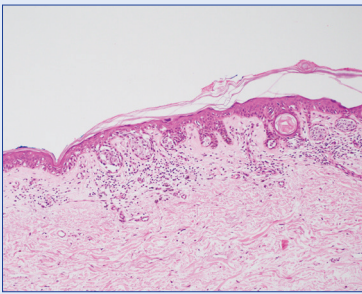


Fig. 2: Melanoma in situ, lentiginous type, showing preservation of rete architecture and a proliferation of single cells as well as small nests.

Key points

- ▶ Excisional biopsies should be performed on small, suspicious lesions as partial biopsies can lead to false positive results.
- ▶ Saucerisation is an excellent technique for removal of small acral lesions but must be deep enough to include the epidermis and dermis.

ACRAL PIGMENTED LESIONS

The differential diagnosis of small acral pigmented lesions includes melanocytic lesions such as acral naevi and acral lentiginous melanoma, as well as non-melanocytic lesions such as tinea nigra and subcorneal haematoma. Dermoscopy can be used to assess the pattern of pigmentation (ridge versus furrow) to aid in the clinical diagnosis and the 'furrow ink test' can help to delineate the furrows. The dermoscopic pattern of subcorneal haematomas can be very similar to that of melanoma, with a parallel ridge pattern seen in many cases. The difference is that, in subcorneal haematoma, the pigmentation in the stratum corneum can be removed by scraping with a sterile needle.

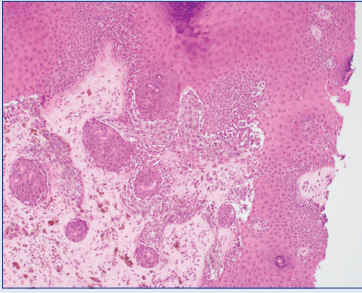


Fig. 3: Poorly blocked and sectioned biopsy of an acral naevus, resulting in long confluent junctional nests resembling acral lentiginous melanoma.

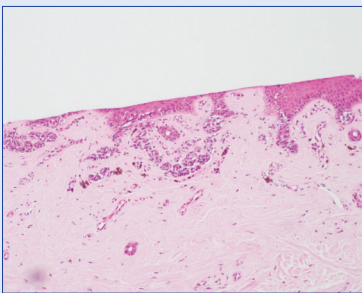


Fig. 4: Acral naevus, same case as in figure 3, following re-embedding and sectioning in a plane perpendicular to ridge/furrow lines. The superficial portion has been lost due to previous poor embedding. The junctional nests are now clearly visible at the tips of the rete and a dermal component is also identified.

Whilst advanced melanoma is often obvious clinically, acral junctional naevi (AJN) can be extremely difficult to distinguish from acral lentiginous melanoma in situ not only clinically but also histologically, for the following reasons. In AJN:

- The entire lesion may be composed of a proliferation of single melanocytes along the dermo-epidermal junction, without any nests
- Pagetoid scatter throughout the entire thickness of the epidermis can be seen centrally

It is essential, therefore, to perform excisional biopsies including a narrow rim of normal skin on all small suspicious acral pigmented lesions. Saucerisation is ideal as wounds heal well but they must be performed properly to ensure that the thick stratum corneum is penetrated to include epidermis and underlying dermis. Histological findings that are reassuring of benignity include:

- Circumscription and symmetry
- The presence of a dermal naevus component
- Lack of pagetoid scatter at the edge of the lesion
- Concentration of nests and single cells at the bases of the rete (furrows) with vertical columns of melanin pigment in the stratum corneum overlying the rete

As naevus nests are concentrated at the bases of the rete (furrows), specimens should be sectioned perpendicular to the furrow pattern. Parallel sections can result in a false impression of asymmetry and confluence of junctional nests. To ensure that specimens are handled appropriately in the laboratory, clinical notes on the request form should specify that the sample is from acral skin.

References:

- DF Lozeau et al. A nongrading histological approach to Clark (dysplastic) nevi: A potential to decrease the excision rate. *Am J Acad Dermatol.* 2016 Jan;74(1).
- C Rosendahl et al. Dysplastic nevus: Fact and fiction. *J Am Acad Dermatol* 2015 Sep;73(3).
- DE Elder. Point: What's in a name? *J Am Acad Dermatol* 2015 Sep;73(3).
- CJ Cockerell. Counterpoint: The 'dysplastic' nevus: What I do and do not believe. *J Am Acad Dermatol* 2015 Sep;73(3).
- SM Swetter et al. Imiquimod 5% cream as primary or adjuvant therapy for melanoma in situ, lentigo maligna type. *J Am Acad Dermatol.* 2015 Jun;72(6).
- K Duffy and D Grossman. The dysplastic nevus: from historical perspective to management in the modern era: part 1. Historical, histologic and clinical aspects. *J Am Acad Dermatol.* 2012 July;67(1).
- D Elston. Practical advice regarding problematic pigmented lesions. *Am J Acad Dermatol.* 2012 July;67(1).
- TL Hocker et al. Favorable long-term outcomes in patients with histologically dysplastic nevi that approach a specimen border. *Am J Acad Dermatol.* 2013;68(4).
- G Kaminska-Winciorek and R Spiewak. Tips and tricks in the dermoscopy of pigmented lesions. *BMC Dermatology* 2012, 12:14.
- FB Puccio and C Chian. Acral junctional nevus versus acral lentiginous melanoma in situ. *Arch Pathol Lab Med.* 2011;135.
- RP Braun et al. The furrow ink test: a clue for the dermoscopic diagnosis of acral melanoma vs nevus. *Arch Dermatol* 2008; 144.
- WHO Classification of Tumours: Pathology and genetics of skin tumours. IARC Press. 2006.
- S Kossard et al. Lentiginous dysplastic naevi in elder: a potential precursor for malignant melanoma. *Australa J Dermatol.* 1991;32(1):27-37.

For further information please contact:

Dr Patricia Renaut FRCPA; MBBS; BSc (Hons)
Consultant Histopathologist
Dermatopathologist

P: (07) 3121 4607 **E:** Patricia.Renaut@qml.com.au

Dr Debra Norris FRCPA; MBBS (HONS)
Pathologist in Charge - Histology

Haematopathologist (member EAHP), Dermatopathologist

P: (07) 3121 4444 **E:** DNorris@qml.com.au